

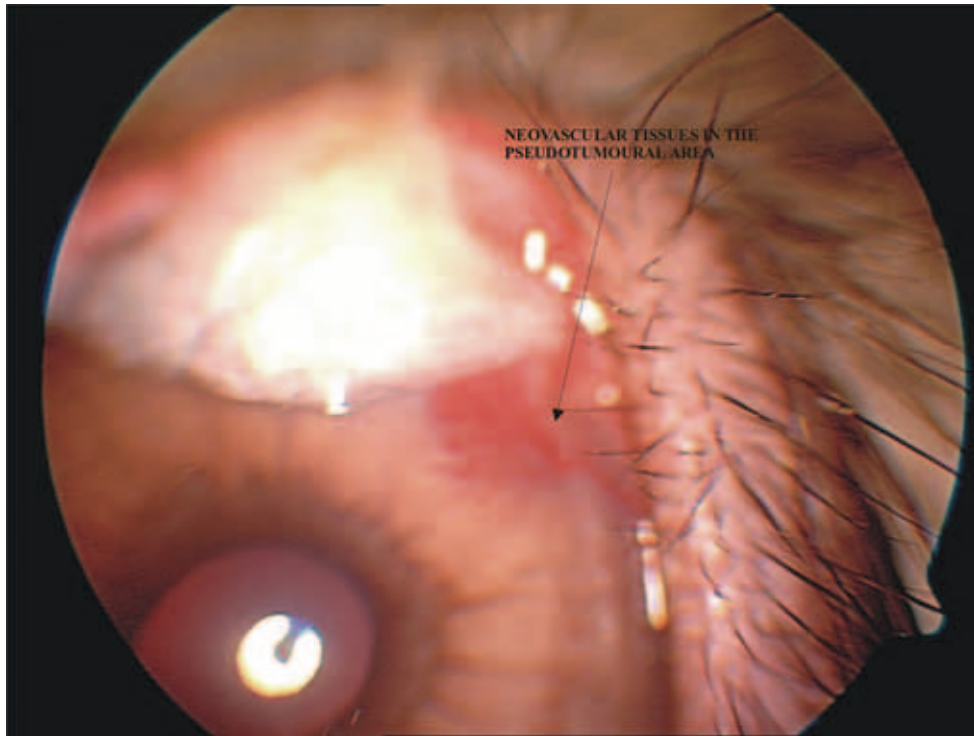Fig. 8 – Pseudotumour in rabbit eye before BG 1120 injection and exposure to radiation.

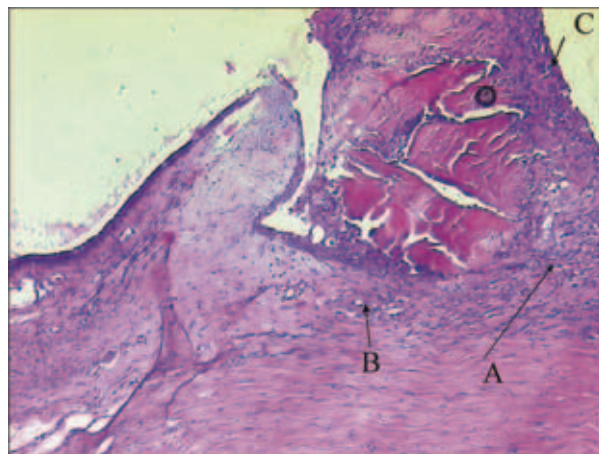


Fig. 9 – 1st eye (non-treated); 80x.

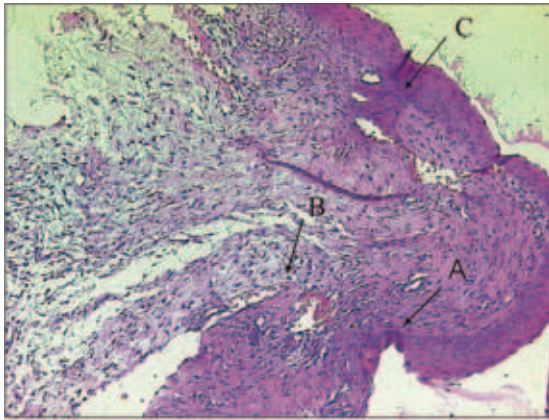


Fig. 10 – 2nd eye (non-irradiated substance); 100×; A – inflammatory cells; B – neovascularisations; C – fibrosis.

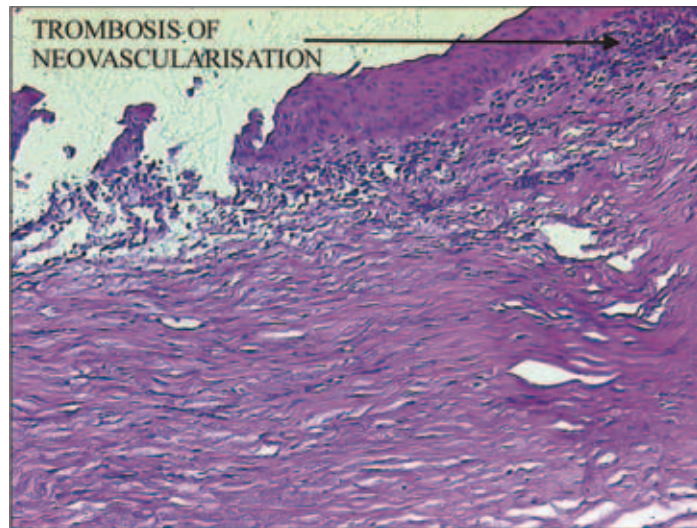


Fig. 11 – 3rd eye (irradiated substance); 100×.

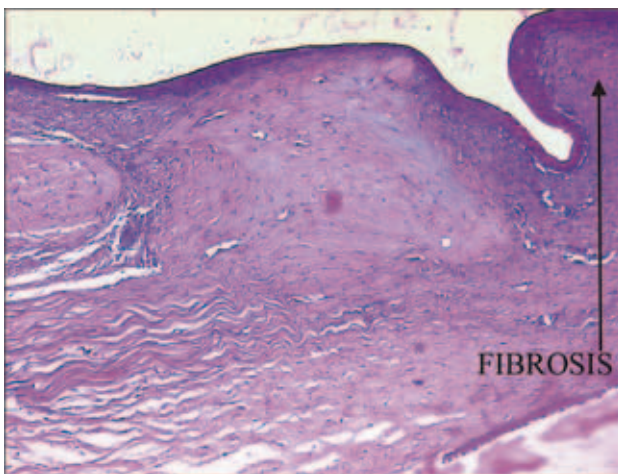


Fig. 12 – 4th eye; 100×.